

## ORIGINAL ARTICLE

# First-In-Human Study of [<sup>64</sup>Cu]Cu-DOTATATE PET/CT in Infective Endocarditis: A Prospective Head-to-Head Comparison With [<sup>18</sup>F]FDG

Katra Hadji-Turdeghal<sup>1</sup> MD; Marie Øbro Fosbøl<sup>1</sup> MD, PhD; Philip Hasbak<sup>1</sup> MD, DMSc; Johan Löfgren<sup>1</sup> MD; Ida Bull Rasmussen<sup>1</sup> MD, PhD; Henning Bundgaard<sup>1</sup> MD, DMSc; Kasper Iversen<sup>1</sup> MD, DMSc; Niels Eske Bruun<sup>1</sup> MD, DMSc; Christian H. Møller<sup>1</sup> MD, PhD; Christian Tuxen, MD, PhD; Helle Hjorth Johannesen, MD; Lars Køber<sup>1</sup> MD, DMSc; Andreas Kjær<sup>1</sup> MD, DMSc; Rasmus Sejersten Ripa<sup>1</sup> MD, DMSc; Emil Loldrup Fosbøl<sup>1</sup> MD, PhD

**BACKGROUND:** Infective endocarditis (IE) can be challenging to diagnose. Positron emission tomography/computed tomography (PET/CT) with 2-deoxy-2-[<sup>18</sup>F]-fluoro-D-glucose ([<sup>18</sup>F]FDG) is recommended as a diagnostic tool in the guidelines, but holds limitations. The aim of this study was to compare the tracer uptake between the novel [<sup>64</sup>Cu]Cu-DOTATATE, which has low cardiac uptake and does not require fasting or dietary restrictions, and [<sup>18</sup>F]FDG in patients with IE and examine the sensitivity and specificity.

**METHODS:** The CuDOS study (Cu-Dotatate Positron Emissions Tomography in Infective Endocarditis) was a prospective study including 20 patients with IE (10 with prosthetic valve endocarditis and 10 with native valve endocarditis) and 20 controls. All participants underwent [<sup>64</sup>Cu]Cu-DOTATATE and [<sup>18</sup>F]FDG PET/CT. Scans were read blinded to clinical data. Tracer uptakes were measured as maximum standardized uptake values in each heart valve. Differences were tested with Wilcoxon rank tests.

**RESULTS:** The median age of the cases and controls was 68 years (interquartile range [IQR], 55.0–75.5) and 61 years (IQR, 57.0–69.5), respectively. [<sup>64</sup>Cu]Cu-DOTATATE uptake (median maximum standardized uptake value [IQR]) in patients with IE was higher than in controls (2.34 [1.40–3.23] versus 1.44 [1.21–1.60];  $P=0.008$ ), although this difference was mainly driven by prosthetic valve endocarditis cases (3.23 [2.02–3.86];  $P<0.001$ ) and not between native valve endocarditis cases and controls (1.51 [1.23–2.58];  $P=0.428$ ). The sensitivity of [<sup>64</sup>Cu]Cu-DOTATATE and [<sup>18</sup>F]FDG PET/CT in 20 cases versus 20 controls were equal, and the specificity was 90% and 75%, respectively. The analysis of prosthetic valve endocarditis versus the 20 controls showed equal sensitivity (80%), and a specificity of 90% and 75%, respectively ( $P=0.38$ ). In addition, a greater proportion of scans achieved diagnostic certainty with [<sup>64</sup>Cu]Cu-DOTATATE PET/CT compared with [<sup>18</sup>F]FDG PET/CT for native valve endocarditis, prosthetic valve endocarditis, and controls.

**CONCLUSIONS:** [<sup>64</sup>Cu]Cu-DOTATATE PET/CT showed uptake in the infected valve in patients with IE, and has major advantage as it does not require any preparation compared with [<sup>18</sup>F]FDG. [<sup>64</sup>Cu]Cu-DOTATATE had a numerically higher specificity than [<sup>18</sup>F]FDG, although the difference was not statistically significant. Both tracers were limited in the detection of native valve endocarditis.

**REGISTRATION:** URL: <https://www.clinicaltrials.gov>; Unique identifier: NCT05432427. [www.clinicaltrialsregister.eu](https://www.clinicaltrialsregister.eu); Unique identifier: 2021-005501-27.

**GRAPHICAL ABSTRACT:** A graphical abstract is available for this article.

**Key Words:** copper DOTATATE CU-64 ■ echocardiography ■ endocarditis ■ heart valve ■ positron emission tomography/computed tomography

Correspondence to: Katra Hadji-Turdeghal, MD, PhD, Department of Cardiology, The Heart Center, Copenhagen University Hospital, Rigshospitalet, Inge Lehmanns Vej 7, DK-2100 Copenhagen, Denmark. Email [katra.hadji-turdeghal@regionh.dk](mailto:katra.hadji-turdeghal@regionh.dk)

Supplemental Material is available at <https://www.ahajournals.org/doi/suppl/10.1161/CIRCIMAGING.124.017156>.

For Sources of Funding and Disclosures, see page XXX.

© 2025 American Heart Association, Inc.

Circulation: Cardiovascular Imaging is available at [www.ahajournals.org/journal/circimaging](http://www.ahajournals.org/journal/circimaging)

### CLINICAL PERSPECTIVE

In this prospective study, a novel positron emission tomography tracer [<sup>64</sup>Cu]Cu-DOTATATE showed uptake in infected valves with infective endocarditis. Future studies are needed to validate our findings; however, [<sup>64</sup>Cu]Cu-DOTATATE has potential to be a useful diagnostic tool in the diagnosis of primarily prosthetic valve endocarditis. [<sup>64</sup>Cu]Cu-DOTATATE has notable advantages; as no preparation, dietary restrictions, or fasting are required before the scan, and in addition in contrast to 2-deoxy-2-[<sup>18</sup>F]-fluoro-D-glucose positron emission tomography/computed tomography, no [<sup>64</sup>Cu]Cu-DOTATATE positron emission tomography/computed tomography scans were interpreted as inconclusive.

### Nonstandard Abbreviations and Acronyms

<b>[<sup>18</sup>F]FDG</b>	2-deoxy-2-[ <sup>18</sup> F]-fluoro-D-glucose
<b>[<sup>64</sup>Cu]Cu-DOTATATE</b>	[ <sup>64</sup> Cu]Cu-[1,4,7,10-tetraazacyclododecane-N,N',N'',N'''-tetra acetic acid]-D-Phe1,Tyr3-octreotate
<b>IE</b>	infective endocarditis
<b>NVE</b>	native valve endocarditis
<b>PET/CT</b>	positron emission tomography/computed tomography
<b>PVE</b>	prosthetic valve endocarditis
<b>SSTR2</b>	somatostatin receptor subtype 2
<b>SUV</b>	standardized uptake value
<b>SUVmax</b>	maximum standardized uptake values
<b>TBR<sub>max</sub></b>	maximum target-to-background ratio
<b>TEE</b>	transesophageal echocardiography

Infective endocarditis (IE) is a severe and potentially fatal disease.<sup>1</sup> Prosthetic valve endocarditis (PVE) is associated with a particularly unfavorable prognosis and accounts for an increasing proportion of the overall IE cases.<sup>2,3</sup> PVE presents significant challenges in terms of diagnosis and treatment. Both transthoracic echocardiography and transesophageal echocardiography (TEE) can be inadequate due to, for instance, shielding, shadowing, or hyper-reflectance from the prosthesis.<sup>4</sup>

2-deoxy-2-[<sup>18</sup>F]-fluoro-D-glucose positron emission tomography/computed tomography ([<sup>18</sup>F]FDG PET/CT) is recommended by the European Society of Cardiology in patients with prosthetic heart valves, when IE is suspected, and TEE is inconclusive.<sup>5,6</sup> However, challenges associated with sensitivity and specificity remain.<sup>7</sup> [<sup>18</sup>F]FDG is a glucose analog, which is taken up by metabolically active cells, and is not specific

for inflammatory cells.<sup>8,9</sup> The preparation for patients before [<sup>18</sup>F]FDG PET/CT scan is comprehensive, involving strict dietary restrictions (24 hours) and a 12-hour fasting period to reduce blood glucose levels and suppress the myocardial uptake of the tracer.<sup>8,10,11</sup> In addition, [<sup>18</sup>F]FDG PET/CT has no or only a limited role in the diagnosis of native valve endocarditis (NVE), and here we may also benefit from better additional diagnostic tools.<sup>5</sup>

The novel [<sup>64</sup>Cu]Cu-DOTATATE is a radiolabeled somatostatin analog with a high binding affinity for SSTR<sub>2</sub> (somatostatin receptor subtype 2).<sup>12,13</sup> The tracer is currently used for diagnosis, monitoring, and treatment of patients with neuroendocrine neoplasms, which express SSTR<sub>2</sub>.<sup>14</sup> SSTR<sub>2</sub> is also highly expressed on the surface of proinflammatory macrophages, which are present in the infected heart valves as part of the inflammatory response to IE.<sup>15</sup> Accordingly, [<sup>64</sup>Cu]Cu-DOTATATE PET/CT could potentially be a better diagnostic tool than [<sup>18</sup>F]FDG PET/CT for identifying IE, both in PVE and NVE. Notably, [<sup>64</sup>Cu]Cu-DOTATATE has almost no cardiac uptake, and does not require fasting, any dietary preparation, or blood glucose restrictions before the scan. Moreover, [<sup>64</sup>Cu]Cu-DOTATATE PET/CT could potentially have a higher specificity, which would be essential to disprove the suspicion of IE.

In the clinical prospective study CuDOS (Cu-Dotate Positron Emissions Tomography in Infective Endocarditis), we aimed to investigate whether [<sup>64</sup>Cu]Cu-DOTATATE showed uptake in infected valves in patients with IE. Subsequently, we aimed to systematically evaluate [<sup>64</sup>Cu]Cu-DOTATATE PET/CT and compare on a head-to-head basis to the current gold standard [<sup>18</sup>F]FDG PET/CT in patients with PVE and NVE versus healthy matched controls.

## METHODS

### Trial Design

The CuDOS trial was an investigator-initiated, monitored, prospective case-control study performed at Copenhagen University Hospital—Rigshospitalet, in the Capital Region of Denmark. All participants provided written informed consent before inclusion. The authors declare that all supporting data are available within the article and its [Supplemental Material](#).

### Study Population

From April 2022 through June 2023, eligible patients were included. Patients had to fulfill the inclusion criteria and have no exclusion criteria to be included. Inclusion criteria were age ≥18 years and the ability to give informed consent. In addition, to be categorized as a case, have definite IE in a native valve (NVE) or definite IE in a prosthetic heart valve (PVE) according to the modified Duke criteria. All cases were discussed in the Endocarditis Team conference, and the diagnosis of definite

IE was based on microbiology results, TEE findings, and minor criteria according to the diagnostic criteria. The diagnosis of IE was determined before the  $[^{18}\text{F}]\text{FDG}$  PET/CT and inclusion into the study. The control group included 10 healthy people without any known diseases and 10 people with a prosthetic heart valve (>1 year since the cardiac surgery due to, for example, aortic/mitral stenosis or regurgitation, who never had IE). The controls were matched according to age ( $\pm 10$  years of difference was allowed) and sex with the case sample. Exclusion criteria were a known allergy to  $[^{64}\text{Cu}]\text{Cu-DOTATATE}$  or  $[^{18}\text{F}]\text{FDG}$ , body weight  $\geq 140$  kg—due to limitations of the scanner, critical illness, or clinical instability. In addition, exclusion criteria comprised pregnancy or suspected pregnancy—negative human chorionic gonadotropin (hCG) was required for fertile women, severe claustrophobia, and insulin-dependent diabetes.

## Clinical Parameters

Information on medical history, prior surgeries, medications, and socioeconomic factors (smoking, alcohol habits, employment status) before the scan was collected from the medical records and confirmed during the inclusion interview. Height and weight were measured, and body mass index was calculated. Laboratory variables, including hemoglobin, white blood cells, C-reactive protein (CRP), kidney parameters, such as estimated glomerular filtration rate, and liver function parameters, such as ALAT (alanine aminotransferase), were measured. Echocardiographic data, such as left ventricular ejection fraction, affected valve, and vegetation size, for all cases were obtained from the diagnostic transthoracic echocardiography/TEE, which was assessed by an IE specialist. The microbiological cause and antibiotic treatment from the time of the diagnosis to the time of the scan were recorded. All data were recorded in an electronic database—Reserach electronic data capture (REDCap) enabled by dynamic data, allowing for continuous monitoring of data validity.<sup>16</sup>

## Cardiovascular Imaging

$[^{64}\text{Cu}]\text{Cu-DOTATATE}$  and  $[^{18}\text{F}]\text{FDG}$  PET/CT were performed, using established methods at the Department of Clinical Physiology and Nuclear Medicine at Copenhagen University Hospital, Rigshospitalet. The scans were scheduled to be performed in a random order after diagnosis and not more than seven days between the two scans. Because of the different effective half-life of the tracers,  $[^{18}\text{F}]\text{FDG}$  PET/CT could be performed no earlier than 48 hours after  $[^{64}\text{Cu}]\text{Cu-DOTATATE}$  PET/CT. If the  $[^{18}\text{F}]\text{FDG}$  PET/CT scan was performed first, at least 12 hours had to pass before the subsequent  $[^{64}\text{Cu}]\text{Cu-DOTATATE}$  PET/CT could be performed.

### $[^{64}\text{Cu}]\text{Cu-DOTATATE}$ Scan

$[^{64}\text{Cu}]\text{Cu-DOTATATE}$  PET/CT was performed 60 minutes (–5 to +15 minutes) after  $[^{64}\text{Cu}]\text{Cu-DOTATATE}$  injection (200 megabecquerel (MBq)), employing an 11-minute acquisition protocol for the whole-body (from glabella to proximal femur) scan and another 10 minutes for a dedicated ECG-gated cardiac scan. The scan was conducted in either a Siemens Biograph mCT or Biograph Vision system (Siemens Healthineers). A low-dose CT (120 keV, mAs 40) with a slice-thickness of 3 mm was performed for the purposes of attenuation correction (AC) and

anatomic localization of the heart valves. No fasting or dietary restriction or preparation was required before the scan, due to very low physiological myocardial uptake.

### $[^{18}\text{F}]\text{FDG}$ Scan

The  $[^{18}\text{F}]\text{FDG}$  PET/CT scan was performed 60 minutes (–5 to +15 minutes) after  $[^{18}\text{F}]\text{FDG}$  injection. The tracer was given as a single dose of 3.0 MBq/kg body weight (maximum 400 MBq). Before injection, serum glucose level was measured. After the injection, the patient was instructed to lie still for 45 to 50 minutes. The day before the scan, the patients were instructed to follow a special diet consisting of very low-carbohydrate and high-fat meals for breakfast, lunch, and dinner to decrease the physiological tracer uptake in the heart muscle. A detailed list of allowed food products was handed out to the patient a couple of days before the scan. Furthermore, a strict 12-hour fasting (as minimum) was required before the scan. Heparin was not administered as part of the preparation in this high-risk group. The scan included an 11-minute acquisition protocol for the whole-body part scan from the glabella to the proximal femur and another 10 minutes for the dedicated ECG-gated cardiac scan. The scan was conducted in either a Siemens Biograph mCT or Biograph Vision system (Siemens Healthineers). The CT scan was diagnostic with an intravenous contrast medium (Visipaque, GE Healthcare) and used for AC and anatomic localization of the heart valves. CT contrast medium was omitted in participants with reduced kidney function (estimated glomerular filtration rate  $\leq 45$  mL/min per  $1.73\text{m}^2$ ).

### $[^{64}\text{Cu}]\text{Cu-DOTATATE}$ and $[^{18}\text{F}]\text{FDG}$ Image Analysis

The two 10-minute cardiac PET acquisitions ( $[^{18}\text{F}]\text{FDG}$  and  $[^{64}\text{Cu}]\text{Cu-DOTATATE}$ ) were each reconstructed into 3 different datasets: a non-ECG-gated reconstruction with AC, an ECG-gated reconstruction (8 cardiac bins) with AC, and a non-ECG-gated reconstruction without AC.

Before analyzing the uptake values, anatomic coregistration of CT and PET scans was carefully verified. The cardiac software Syngovia Frontier (Siemens, AG; Healthcare Sector, Germany) was used to analyze the images. The standardized uptake value (SUV), which is a semiquantitative measurement of uptake in the tissue, was reported for each heart valve. In addition, maximum target-to-background ratio ( $\text{TBR}_{\text{max}}$ ) was calculated using the blood pool mean SUV ( $\text{SUV}_{\text{mean}}$ ) in the right atrium as background. To ensure blinding, the reader (Chief Physician at the Department of Clinical Physiology and Nuclear Medicine) involved in the imaging analysis was blinded to the clinical details (endocarditis or not) and thus the group the patients were allocated to. First, all ( $n=40$ )  $[^{18}\text{F}]\text{FDG}$  PET/CT were analyzed; 3 to 4 weeks later all ( $n=40$ )  $[^{64}\text{Cu}]\text{Cu-DOTATATE}$  PET/CT were analyzed to avoid memory of the previous scans.

First, the reader determined if the scan quality allowed for assessment of the tracer uptake in the heart valves. Next, quantitative uptake in each of the heart valves was then determined using static stacked axial PET/CT images, and volumes of interest were drawn using the anatomic information from the CT to include the heart valves and volumes of interest in the right atrium as background. The tracer uptake was corrected for the injected dose, patient weight, and time to acquisition as the maximal standardized uptake value ( $\text{SUV}_{\text{max}}$ ) and calculated for each volume of interest using non-ECG-gated reconstructions of the PET with AC (both  $[^{18}\text{F}]\text{FDG}$  and

$^{64}\text{Cu}$ Cu-DOTATATE). Finally, the same experienced reader quantified the tracer uptake as either absent, focal/multifocal, diffuse-heterogeneous, or diffuse-homogeneous. Based on this the scan was scored as 'suspicious of IE' (focal/multifocal or diffuse-heterogeneous), 'not suspicious of IE' (absent or diffuse-homogeneous), or 'inconclusive', and the level of certainty of this conclusion as high (definite) or low (possible) using all the 3 reconstructions of the PET ( $-/+$  AC and  $\pm$ ECG-gating). For the healthy controls, the  $\text{SUV}_{\text{max}}$  was calculated as an average of the  $\text{SUV}_{\text{max}}$  in the aortic and mitral valves.

## Outcomes

The primary outcome was the comparison of tracer uptake ( $\text{SUV}_{\text{max}}$ ) at the site of infection according to findings on the diagnostic TEE between  $^{64}\text{Cu}$ Cu-DOTATATE PET/CT and  $^{18}\text{F}$ FDG PET/CT in controls and cases. Secondary outcomes were sensitivity and specificity of  $^{64}\text{Cu}$ Cu-DOTATATE PET/CT and  $^{18}\text{F}$ FDG PET/CT for PVE and NVE, respectively. IE cases were defined as PVE or NVE cases at the Department of Cardiology by an endocarditis multidisciplinary team according to the modified Duke criteria.<sup>5,6</sup> The  $^{64}\text{Cu}$ Cu-DOTATATE and  $^{18}\text{F}$ FDG PET/CT examinations were scored by a Chief Physician in nuclear cardiology as specified above. In the sensitivity and specificity analyses, the inconclusive scans in the control group counted as a false positive, and the inconclusive scans in the case group counted as a false negative.

## Statistical Analysis

### Statistics

Baseline characteristics are presented with counts and percentages for categorical variables and medians (interquartile ranges [IQRs]) for continuous variables. Nonparametric unpaired Wilcoxon rank tests were applied for continuous variables and Fisher exact tests for categorical variables were applied to assess whether clinical characteristics differed between the groups. To assess differences in  $\text{SUV}_{\text{max}}$  uptake between groups for  $^{64}\text{Cu}$ Cu-DOTATATE and  $^{18}\text{F}$ FDG PET/CT respectively, unpaired Wilcoxon rank tests were applied. To assess the difference in TBR between the two scans, we used paired Wilcoxon signed rank. For cases and for controls, we performed McNemar test to compare sensitivities and specificities. To estimate the difference in sensitivity and specificity, respectively, a generalized estimating equations analysis for paired binary data was used—for cases and controls separately. Five randomly selected scans from each of the 3 patient groups (in total 15 scans  $\approx$ 38% of the total number of scans) were reassessed blinded by the same Chief Physician in Nuclear Medicine >12 months after the first assessment. Reproducibility of valvular  $^{64}\text{Cu}$ Cu-DOTATATE  $\text{SUV}_{\text{max}}$  was assessed using the intraclass correlation coefficient (a mixed effects model with absolute limits of agreement). For all tests,  $P < 0.05$  represented statistical significance. All statistical data management and analyses were performed using the SAS statistical software, version 9.4. (SAS Institute Inc, Cary, NC).

### Power Calculations

Our study was hypothesis-generating and explorative, and limited evidence for sample size calculation for these novel measures is yet available. Based on an expected specificity of 90%

in  $^{64}\text{Cu}$ Cu-DOTATATE scan, meaning the detection of 90% of patients with IE compared with  $^{18}\text{F}$ FDG scan, which has a specificity of 75% and a significant level of 0.05 ( $\alpha = 0.05$ ), we needed to have a sample size of a minimum of 40 patients (IE according to modified Duke criteria and no IE). We decided to include 40 patients (20 with verified IE according to the modified Duke criteria and 20 healthy individuals with no IE).

## Ethics

The study design was approved by the Danish Medicines Agency, the Regional Scientific Ethics Committee (H-21040764), and the Danish Data Protection Agency (P-2021-571). The study was monitored by the Good Clinical Practice unit in the Capital Region of Denmark according to the International Committee on Harmonization of Good Clinical Practice (ICH-CGP) regulations. The study was performed in accordance with the principles of the Declaration of Helsinki (version 2013).

## RESULTS

### Study Population

We included 20 cases and 20 controls. The median age in the case sample was 68 years (IQR, 55.0–75.5), and in the control sample, it was 61 years (IQR, 57.0–69.5). The case sample generally had a higher burden of comorbidities. The baseline characteristics of the study sample are shown in Table 1. The median number of days between scans in the case sample was 2.5 (IQR, 1.0–6.0) and in the control sample, 6.0 (IQR, 6.0–8.0;  $P < 0.001$ ). The median injected dose of the tracer  $^{64}\text{Cu}$ Cu-DOTATATE in the case and control sample was 197 MBq (IQR, 189–203) and 200 MBq (IQR, 192–206;  $P = 0.71$ ), respectively. The median dose of  $^{18}\text{F}$ FDG in case and control sample was 232 MBq (IQR, 221–259) and 249 MBq (IQR, 226–278) ( $P = 0.32$ ), respectively. The median number of days between antibiotic treatment initiation and the first PET/CT scan in the case sample was 5.0 days (IQR, 3.0–6.5). When the case sample was subdivided into PVE cases and NVE cases, the corresponding numbers were of 5.0 days (IQR, 3.0–12.0) and 5.0 days (IQR, 5.0–6.0;  $P = 0.94$ ), respectively.

### IE Characteristics

Six (60%) patients had aortic valve IE, 3 (30%) had mitral valve IE, and one (10%) patient had both mitral and aortic valve IE. The median left ventricular ejection fraction was 60% (IQR, 60.0%–60.0%), and the median vegetation size was 14.5 mm (IQR, 13.0–19.0). The most common microbiological cause in NVE cases was *Staphylococcus aureus* (40%; Table 2; Figure 1). In the NVE group, 3 (30%) patients underwent surgery after the PET/CT scans; the remaining sample was treated conservatively. In one of the surgically managed patients, the extracted valve showed growth of *Propionibacterium acnes*; in another, the extracted valve was not sent for

**Table 1. Baseline Characteristics Cases vs Controls, NVE, and PVE**

Characteristic	Cases; n=20 (%)	NVE; n=10 (%)	PVE; n=10 (%)	Controls; n=20 (%)	P value*
No. of patients	20 (100)	10 (100)	10 (100)	20 (100)	...
Age, y [IQR]	68.0 [55.0–75.5]	64.0 [54.0–76.0]	69.5 [56.0–74.0]	60.5 [57.0–69.5]	0.370
Sex (male)	17 (85.0)	8 (80.0)	9 (90.0)	14 (70.0)	...
Weight, kg [IQR]	75.5 [71.5–83.0]	74.5 [70.5–82.5]	76.5 [74.0–83.0]	80.0 [70.5–91.0]	0.379
Height, cm [IQR]	174.5 [171.5–180.0]	174.5 [171.0–180.0]	175.0 [172.0–180.0]	179.5 [170.0–183.0]	0.464
BMI, kg/m <sup>2</sup> [IQR]	24.6 [24.0–26.8]	24.2 [24.1–25.4]	25.7 [23.9–27.2]	25.4 [23.1–27.4]	0.828
Comorbidities					
Prosthetic heart valve	10 (50)	0 (0)	10 (100)	10 (50)	1.000
Prior CABG	5 (25)	2 (20)	3 (30)	1 (5)	0.182
Prior CIED	0 (0)	0 (0)	0 (0)	2 (10)	0.487
Atrial fibrillation/flutter	9 (45)	3 (30)	6 (60)	2 (10)	0.031
Heart failure	3 (15)	1 (10)	2 (20)	1 (5)	0.605
Ischemic heart disease	5 (25)	2 (20)	3 (30)	2 (10)	0.408
Diabetes	4 (20)	1 (10)	3 (30)	0	0.106
Prior cancer	2 (10)	1 (10)	1 (10)	1 (5)	1.000
Tobacco					1.000
Never	12 (60)	6 (60)	6 (60)	11 (55)	
Current	3 (15)	2 (20)	1 (10)	3 (15)	
Exsmoker	5 (25)	2 (20)	3 (30)	6 (30)	
Alcohol					0.612
Never	7 (35)	3 (30)	4 (40)	5 (25)	
<7/14 units per week	11 (55)	7 (70)	4 (40)	14 (70)	
>7/14 units per week	2 (10)	0 (0)	2 (20)	1 (5)	
Medication					
Antithrombotic treatment	15 (75)	5 (50)	10 (100)	7 (35)	0.025
Statins	11 (55)	3 (30)	8 (80)	4 (20)	0.048
Immunosuppressant	2 (10)	1 (10)	1 (10)	1 (5)	1.000
Glucocorticoids	0	0	0	0	
Other	2 (10)	1 (10)	1 (10)	1 (5)	
Laboratory results					
Hgb, mmol/L [IQR]	6.9 [6.2–7.7]	6.8 [6.2–8.1]	7.0 [5.5–7.4]	8.9 [8.0–9.3]	<0.001
Creatinine, $\mu$ mol/L [IQR]	84.0 [71.2–124.5]	90.5 [71.0–128.0]	79.5 [72.0–121.0]	72.0 [61.5–79.0]	0.039
eGFR, mL/min per 1.73m <sup>2</sup> [IQR]	79.0 [49.0–90.0]	66.0 [49.0–90.0]	83.5 [51.0–90.0]	90.0 [72.0–90.0]	0.045
ALAT (U/L) [IQR]	27.5 [18.0–31.5]	26.5 [17.0–31.0]	27.5 [19.0–34.0]	29.5 [22.0–35.5]	0.343
Leukocytes, $\times 10^9$ /L [IQR]	9.6 [6.9–11.8]	10.2 [7.8–11.4]	7.5 [6.3–12.2]	6.7 [5.6–8.1]	0.011
CRP, mg/L [IQR]	35.0 [20.5–77.0]	36.5 [30.0–97.0]	35.0 [12.0–55.0]	3.0 [2.0–4.0]	<0.001

ALAT indicates alanine aminotransferase; BMI, body mass index; CABG, coronary artery bypass surgery; CIED, cardiovascular implantable electronic device; CRP, C-reactive protein; eGFR, estimated glomerular filtration rate; Hgb, hemoglobin; IQR, interquartile range; NVE, native valve endocarditis; and PVE, prosthetic valve endocarditis.

\*P values reported for cases (n=20) vs controls (n=20).

analysis; in the third patient, the, microbiological tests from the resected valve were without bacterial findings.

All PVE cases had definite IE according to the modified Duke criteria. Four (40%) patients had IE in a biological aortic valve prosthesis, one (10%) patient in a mechanical aortic prosthesis, 3 (30%) patients in a biological mitral prosthesis, one (10%) patient in both aortic and pulmonary prostheses, and one (10%) patient in only the arcus aortic prosthesis (initially, this patient was suspected

of having definite IE in both the aortic arch prosthesis and biological aortic valve prosthesis; however, later, the diagnostic workup showed this patient had IE only in the prosthesis in the aortic arch and, no IE in the biological prosthesis). The median left ventricular ejection fraction was 58% (IQR, 50.0%–60.0%), and the median vegetation size was 18.5 mm (IQR, 12.0–21.0). The most common microbiological etiologies in the PVE sample were *Streptococcus mitis* (30%) and *Staphylococcus aureus*

**Table 2. Overview of the Echocardiographic Data, Antibiotic, and Surgical Treatment for NVE and PVE**


	NVE (n=10)	PVE (n=10)
Echocardiographic data		
LVEF, % median [IQR]	60% [60.0%–60.0%]	58% [50.0%–60.0%]
Vegetations size, mm [IQR]	14.5 [13.0–19.0]	18.5 [12.0–21.0]
Affected valve		
Aortic valve		
Native	6 (60%)	
Prosthesis		
Biological	...	4 (40%)
Mechanical	...	1 (10%)
Mitral valve		
Native	3 (30%)	
Prosthesis		
Biological	...	3 (30%)
Mechanical	...	...
Both aortic and mitral valve	1 (10%)	
Both aortic and pulmonary valve (mechanical aortic valve and Melody transcatheter pulmonary valve)		1 (10%)
Aortic prosthesis		1 (10%)
Treatment		
Surgery	3 (30%)	2 (20%)
Medical	7 (70%)	8 (80%)
Antibiotic treatment		
β-lactam antibiotic+another antibiotic (combination therapy with either vancomycin, gentamicin, or rifampicin/moxifloxacin)	10 (100%)	7 (70%)
Vancomycin+gentamicin+rifampicin	...	2 (20%)
Another antibiotic combination therapy	...	1 (10%)

IQR indicates interquartile range; LVEF, left ventricular ejection fraction; NVE, native valve endocarditis; and PVE, prosthetic valve endocarditis.

(20%; Table 2; Figure 1). In the PVE sample, two (20%) patients underwent surgery after the PET/CT scans; the remaining sample was treated conservatively. In one of the surgically managed patients, the extracted valve showed growth of nonhemolytic *Streptococcus salivarius* group, and in the other, the extracted valve showed no microbiological growth.

[<sup>64</sup>Cu]Cu-DOTATATE and [<sup>18</sup>F]FDG Uptake in Patients With IE

The median SUV<sub>max</sub> of the affected heart valve on [<sup>64</sup>Cu]Cu-DOTATATE PET for cases was 2.34 (IQR, 1.40–3.23] and for controls 1.44 (IQR, 1.21–1.60]. There was a significant difference in the uptake (*P* =0.008). When



**Figure 1. Overview of the microbiological species in the case sample subdivided into prosthetic valve endocarditis (PVE) and native valve endocarditis (NVE).**

subdividing the case sample and comparing it to the 20 controls, we found a significant difference in the  $\text{SUV}_{\text{max}}$  between controls and PVE cases (median  $\text{SUV}_{\text{max}}$  3.23 [IQR, 2.02–3.86];  $P < 0.001$ ). There was no statistically significant difference in the uptake between NVE cases and controls (median  $\text{SUV}_{\text{max}}$  1.51 [IQR, 1.23–2.58];  $P = 0.428$ ; Figure 2).

The median  $\text{SUV}_{\text{max}}$  in the  $[^{18}\text{F}]\text{FDG}$  PET/CT scan for cases was 5.30 (IQR, 2.86–7.67), and for controls, it was 2.50 (IQR, 2.14–3.63). There was a significant difference in the uptake ( $P = 0.003$ ).

When subdividing the case sample, we found a significant difference in the  $\text{SUV}_{\text{max}}$  between controls and PVE cases (median  $\text{SUV}_{\text{max}}$  7.06 [IQR, 6.0–11.26];  $P < 0.001$ ). There was no statistically significant difference between NVE cases and controls (median  $\text{SUV}_{\text{max}}$  3.35 [IQR, 2.29–4.86];  $P = 0.441$ ; Figure 3).

Assessment of the reproducibility of valvular  $[^{64}\text{Cu}]\text{Cu-DOTATATE}$   $\text{SUV}_{\text{max}}$  showed an intrarater variability of  $\pm 0.046$ , which gives an intraclass correlation coefficient of 0.97.

Representative examples of the uptake of  $[^{64}\text{Cu}]\text{Cu-DOTATATE}$  and  $[^{18}\text{F}]\text{FDG}$  in patients with PVE, NVE, and healthy controls are shown in Figure 4.  $[^{64}\text{Cu}]\text{Cu-DOTATATE}$  PET/CT and  $[^{18}\text{F}]\text{FDG}$  PET/CT scans of all included patients with PVE ( $n=10$ ) and native valve endocarditis ( $n=10$ ) are shown in Figures S1 through S3.

The median  $\text{TBR}_{\text{max}}$  with  $[^{64}\text{Cu}]\text{Cu-DOTATATE}$  PET for cases was 3.71 (IQR, 2.46–6.53) and for controls 2.69 (IQR, 2.35–3.32). There was a significant difference in

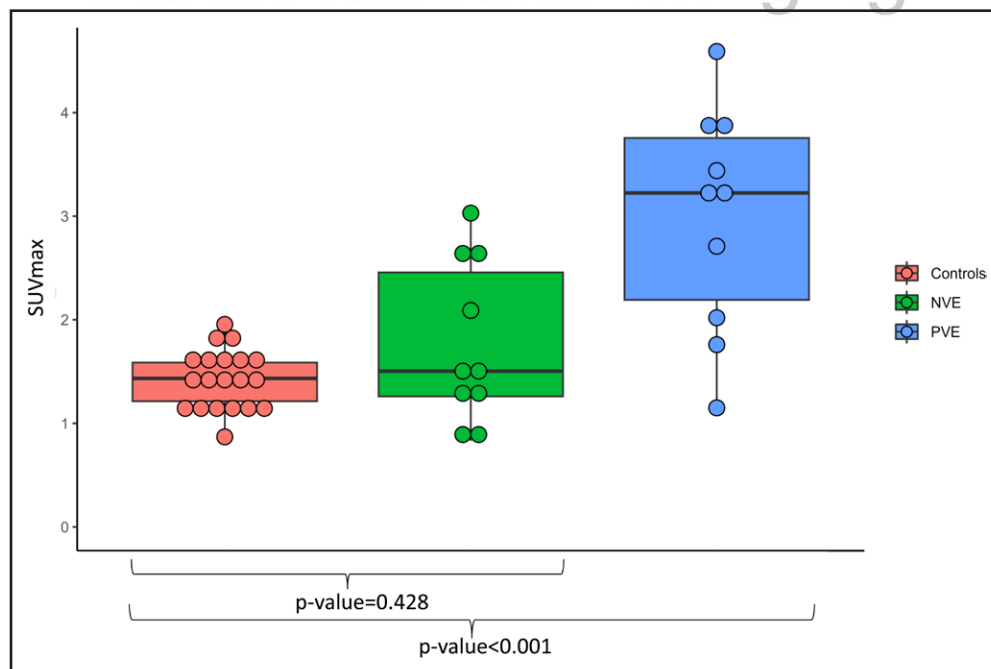
the uptake ( $P = 0.024$ ). When subdividing the case sample and comparing it with the 20 controls, we found a significant difference in the  $\text{TBR}_{\text{max}}$  between controls and the PVE cases (median  $\text{TBR}_{\text{max}}$  5.71 [IQR, 3.54–9.17];  $P < 0.001$ ). There was no statistically significant difference in the uptake between controls and the NVE cases (median  $\text{TBR}_{\text{max}}$  2.71 [IQR, 2.31–3.87];  $P = 0.843$ ).

The median  $\text{TBR}_{\text{max}}$  with  $[^{18}\text{F}]\text{FDG}$  PET for cases was 2.93 (IQR, 1.96–4.39) and for controls 1.67 (IQR, 1.38–2.17). There was a significant difference in the uptake ( $P < 0.001$ ). When subdividing the case sample and comparing it with the 20 controls, we found a significant difference in the  $\text{TBR}_{\text{max}}$  between controls and the PVE cases (median  $\text{TBR}_{\text{max}}$  4.06 [IQR, 2.93–6.29];  $P < 0.001$ ). There was no statistically significant difference in the uptake between controls and the NVE cases (median  $\text{TBR}_{\text{max}}$  2.12 [IQR, 1.83–2.44];  $P = 0.253$ ). Examples of the uptake of  $[^{64}\text{Cu}]\text{Cu-DOTATATE}$  in the myocardium and the blood pool, with comparisons to  $[^{18}\text{F}]\text{FDG}$  are shown in Figure S4. The median blood uptake of  $[^{64}\text{Cu}]\text{Cu-DOTATATE}$  was 0.51 (IQR, 0.39–0.59) and for  $[^{18}\text{F}]\text{FDG}$  1.54 (IQR, 1.25–1.77),  $P < 0.0001$ .



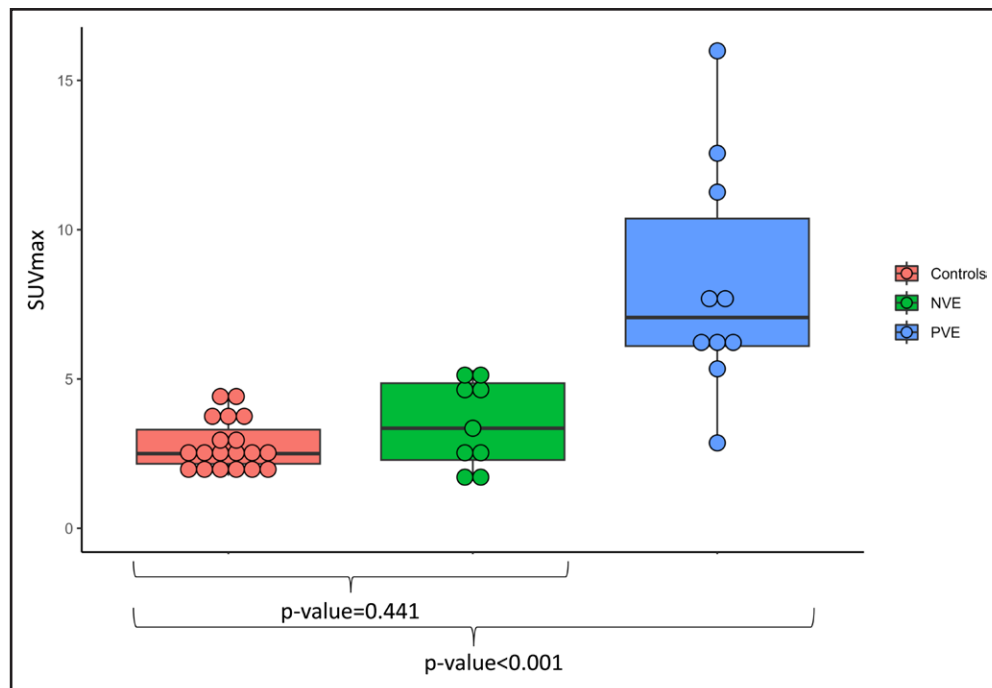
### Cardiac Uptake Versus the Clinical Diagnosis of IE—Sensitivity and Specificity

In total, there were 6 'inconclusive'  $[^{18}\text{F}]\text{FDG}$  PET/CT scans due to high physiological uptake of the tracer—four 'inconclusive' in the control sample and two in the



**Figure 2. Uptake of  $[^{64}\text{Cu}]\text{Cu-DOTATATE}$ .**

Box plot of the maximum standardized uptake value ( $\text{SUV}_{\text{max}}$ ) of  $[^{64}\text{Cu}]\text{Cu-DOTATATE}$  positron emission tomography/computed tomography in controls, prosthetic valve endocarditis (PVE), and native valve endocarditis (NVE).



**Figure 3. Uptake of  $^{18}\text{F}$ fluorodeoxyglucose ( $^{18}\text{F}$ FDG).**

Box plot of the maximum standardized uptake value ( $\text{SUV}_{\text{max}}$ ) of  $^{18}\text{F}$ FDG positron emission tomography/computed tomography in controls, prosthetic valve endocarditis (PVE), and native valve endocarditis (NVE). In 1 control and 1 NVE case, it was not possible to assess the  $\text{SUV}_{\text{max}}$  uptake.

case sample. There were no 'Inconclusive' scan results with  $^{64}\text{Cu}$ ]Cu-DOTATATE PET/CT (Figure 5).

The sensitivity and specificity of  $^{18}\text{F}$ FDG PET/CT in the 20 cases and the 20 controls were 55% (95% CI, 33–77) and 75% (95% CI, 56–94), respectively. This corresponded to a positive predictive value (PPV) of 69% (95% CI, 46–91) and a negative predictive value (NPV) of 63% (95% CI, 43–82).

The sensitivity and specificity of  $^{64}\text{Cu}$ ]Cu-DOTATATE PET/CT in the 20 cases and the 20 controls were 55% (95% CI, 33–77) and 90% (95% CI, 77–100), respectively. This corresponded to a PPV of 85% (95% CI, 65–100) and an NPV of 67% (95% CI, 49–84) in our sample with a prevalence of 50% (Figure 6A).

The analysis of NVE versus 20 controls showed for  $^{18}\text{F}$ FDG PET/CT a sensitivity of 30% (95% CI, 2–58) and specificity of 75% (95% CI, 56–94%). This is equivalent to a PPV of 38% (95% CI, 4–71) and an NPV of 68% (95% CI, 49–88). For  $^{64}\text{Cu}$ ]Cu-DOTATATE PET/CT, the sensitivity was also 30% (95% CI, 2–58), and the specificity was 90% (95% CI, 77–100). This is equivalent to a PPV of 60% (95% CI, 17–100) and an NPV of 72% (95% CI, 54–90; Figure 6B).

The analysis of PVE versus 20 controls showed for  $^{18}\text{F}$ FDG PET/CT a sensitivity of 80% (95% CI, 55–100) and a specificity of 75% (95% CI, 56–94). This is equivalent to a PPV of 62% (95% CI, 35–88) and an NPV of 88% (95% CI, 73–100). For  $^{64}\text{Cu}$ ]Cu-DOTATATE PET/CT, the sensitivity was also 80% (95% CI, 55–100), and

the specificity was 90% (95% CI, 77–100). This is equivalent to a PPV of 80% (95% CI, 55–100) and an NPV of 90% (95% CI, 77–100; Figure 6C).

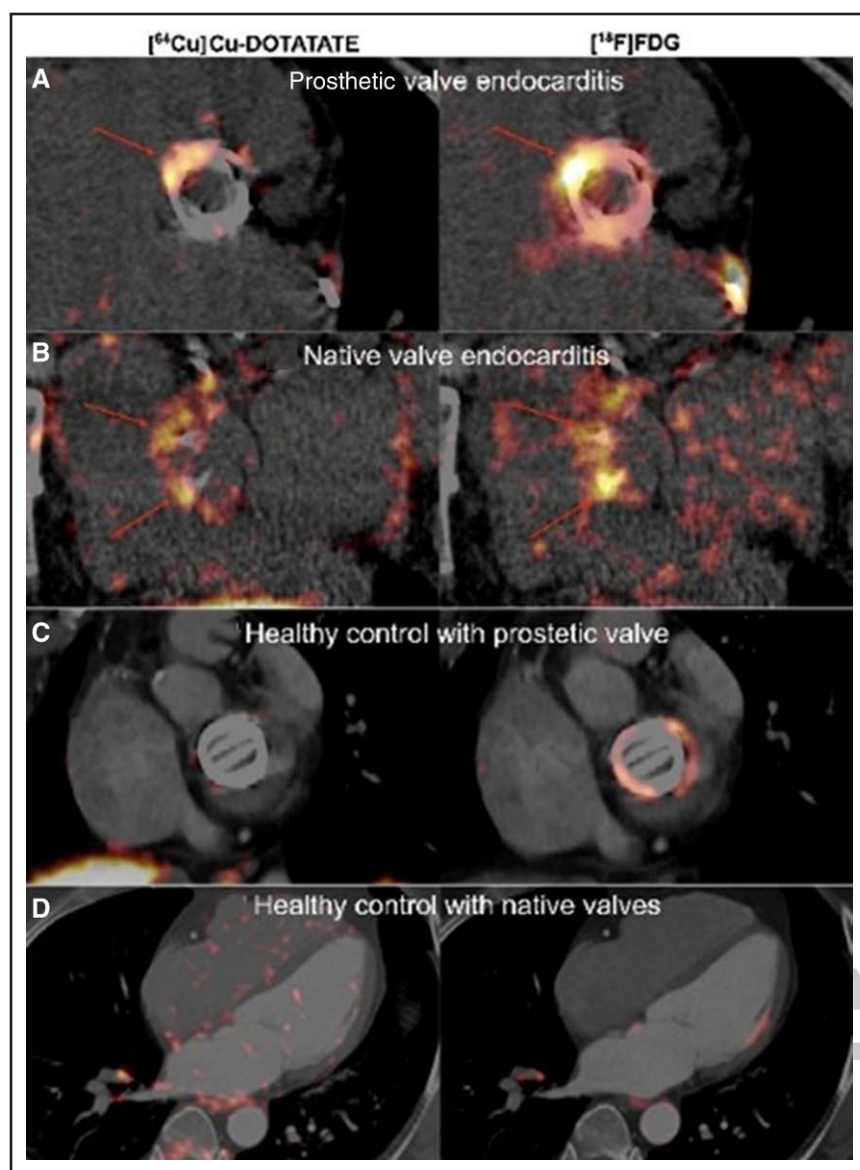
The difference in specificity between  $^{64}\text{Cu}$ ]Cu-DOTATATE and  $^{18}\text{F}$ FDG was 15% (IQR, 5.9%–36%;  $P=0.38$ ). The estimated sensitivities were equal, and no CIs for the differences could be calculated.

As one patient did not have PVE in the biological aortic valve, we conducted a sensitivity analysis for 9 PVE cases versus 20 controls without this patient. For  $^{64}\text{Cu}$ ]Cu-DOTATATE PET/CT, the sensitivity was 89% (95% CI, 67–100), and the specificity was 90% (95% CI, 77–100). This is equivalent to a PPV of 80% (95% CI, 55–100) and an NPV of 95% (95% CI, 85–100).  $^{18}\text{F}$ FDG PET/CT also had a sensitivity of 89% (95% CI, 68–100) but a specificity of 75% (95% CI, 56–94). This is equivalent to a PPV of 62% (95% CI, 35–88) and an NPV of 94% (95% CI, 82–100; Figure S5).

The results of the visual assessment of the tracer uptake by the reader can be found in Tables S1 and S2.

### Certainty–Assurance in the Assessment of Cardiac Foci

In the analysis of assurance of the certainty in the assessment of the cardiac foci  $^{64}\text{Cu}$ ]Cu-DOTATATE PET/CT, a higher percentage of scans were deemed as high (definitive), and a lower percentage of scans were deemed as low(possible) or not interpretable in the NVE cases, PVE



**Figure 4. Comparison of uptake of  $[^{64}\text{Cu}]\text{Cu-DOTATATE}$  and 2-deoxy-2- $[^{18}\text{F}]\text{fluoro-d-glucose}$  ( $[^{18}\text{F}]\text{FDG}$ ).**

No preparation was required for the  $[^{64}\text{Cu}]\text{Cu-DOTATATE}$  positron emission tomography (PET), whereas the  $[^{18}\text{F}]\text{FDG}$  PET was performed after a high fat and very low-carbohydrate diet with subsequent >12-hour fast. **A**, Patient with biological aortic valve and definite infective endocarditis. Both PET tracers show suspect focal uptake (green arrows). **B**, Patient with native valves and definite infective endocarditis. Both tracers show multifocal diffuse uptake (green arrows) in a calcified native aortic valve. **C**, Patient with mechanic mitral valve prosthesis. No clinical suspicion of infective endocarditis. No uptake of  $[^{64}\text{Cu}]\text{Cu-DOTATATE}$  in the prosthetic valve. Homogeneous uptake of  $[^{18}\text{F}]\text{FDG}$  around the prosthetic valve points to reactive inflammation and not infective endocarditis. **D**, Healthy control subject with native valves. No increased uptake of any of the 2 PET tracers in the mitral valve (annulus marked with red arrows).

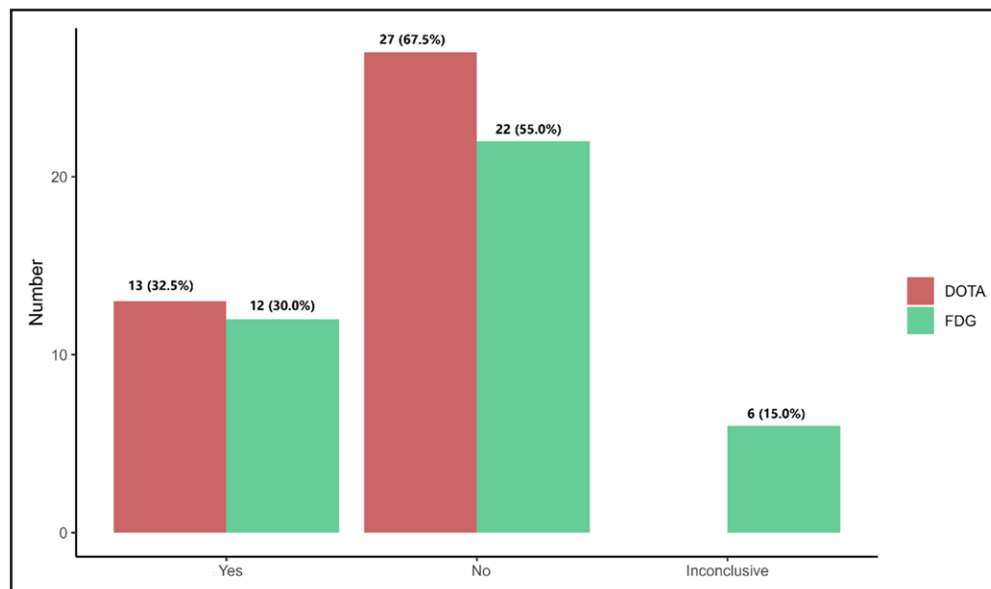
cases, and controls compared with  $[^{18}\text{F}]\text{FDG}$  PET/CT (Figure 7). Examples with reduced certainty of the diagnosis from the  $[^{18}\text{F}]\text{FDG}$  PET due to poor suppression of myocardial  $[^{18}\text{F}]\text{FDG}$  uptake are shown in (Figure S6).

## DISCUSSION

This is the first study to investigate the uptake of  $[^{64}\text{Cu}]\text{Cu-DOTATATE}$  PET/CT in patients with IE and to compare it with  $[^{18}\text{F}]\text{FDG}$  PET/CT. In this comparative and prospective PET/CT study in patients with IE, we had 3 main findings. First,  $[^{64}\text{Cu}]\text{Cu-DOTATATE}$  showed uptake in infected heart valves comparable to  $[^{18}\text{F}]\text{FDG}$  PET/CT. Second, in contrast to  $[^{18}\text{F}]\text{FDG}$  PET/CT, no  $[^{64}\text{Cu}]\text{Cu-DOTATATE}$  PET/CT scans were deemed inconclusive. Furthermore, in contrast to  $[^{18}\text{F}]\text{FDG}$  PET/CT, no preparation is needed before  $[^{64}\text{Cu}]\text{Cu-DOTATATE}$  PET/CT scan. Third, our results showed that the sensitivity and

specificity of  $[^{64}\text{Cu}]\text{Cu-DOTATATE}$  and  $[^{18}\text{F}]\text{FDG}$  PET/CT performed equally poorly in identifying NVE and equally well in identifying PVE.

$[^{64}\text{Cu}]\text{Cu-DOTATATE}$  PET/CT showed uptake in the infected heart valves. Histologically, it has previously been described that patients with infected prosthetic valves have a more concentrated presence of macrophages on the valve compared with those with NVE, where polymorphonuclear leukocytes such as neutrophil granulocytes are more predominant.<sup>15,17,18</sup> This could explain why the sensitivity in PVE cases was higher compared with those with NVE. The uptake in the controls with prosthetic heart valves and native valves was similarly low, which shows the higher uptake in relation to patients with PVE is related to the infection in/around the valve and not just the prosthesis itself. In a study by Toner et al in a systematic comparison of  $[^{64}\text{Cu}]\text{Cu-DOTATATE}$  and  $[^{18}\text{F}]\text{FDG}$  PET/CT in mouse and rabbit models,



**Figure 5. Cardiac foci assessed visually in 2-deoxy-2-[ $^{18}\text{F}$ ]-fluoro-d-glucose positron emission tomography/computed tomography ( $^{18}\text{F}$ ]FDG PET/CT; FDG) and [ $^{64}\text{Cu}$ ]Cu-DOTATATE (DOTA) PET/CT blindly without the knowledge of the clinical status (infective endocarditis [IE] case or control).**

Yes denotes visually interpreted as presence of IE, No denotes visually interpreted as no presence of IE, Inconclusive denotes not possible to visually interpret the scan as either Yes or No. There were no inconclusive scans with [ $^{64}\text{Cu}$ ]Cu-DOTATATE PET/CT.



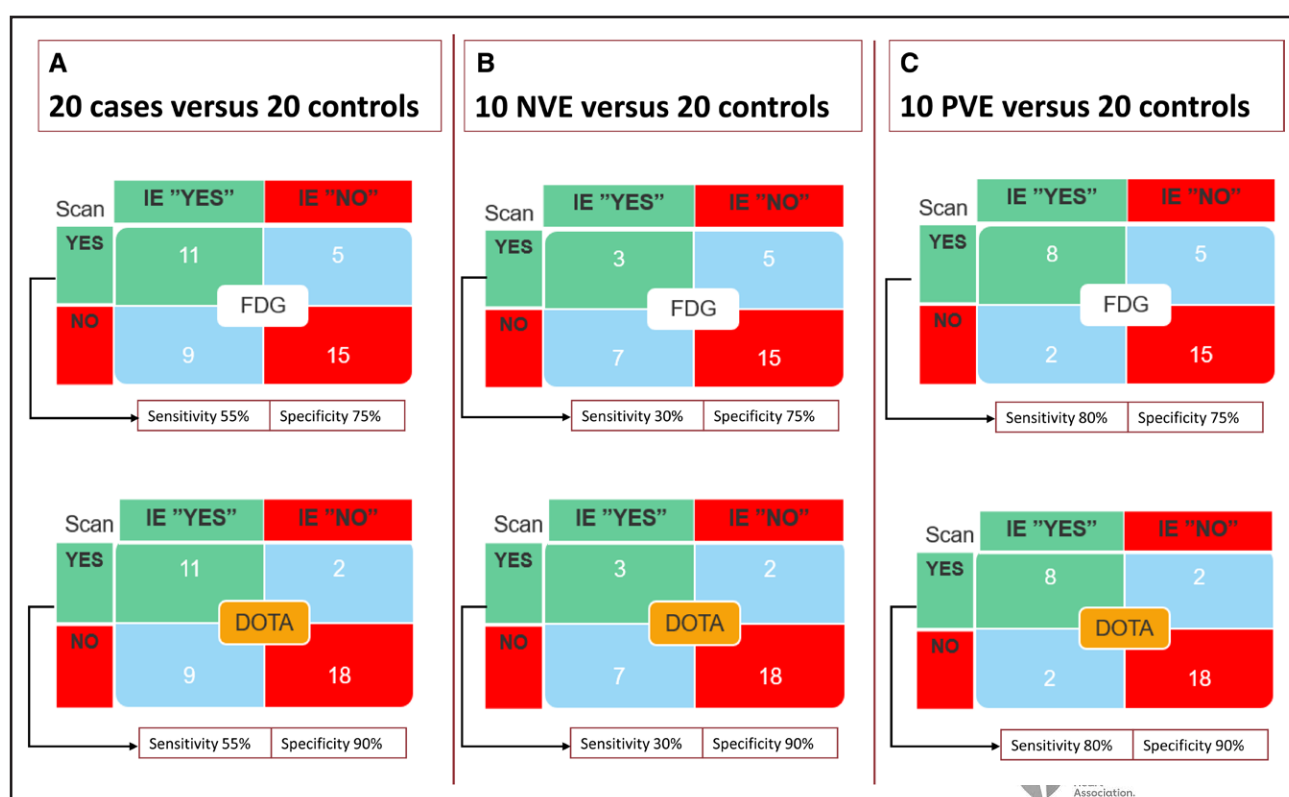
[ $^{64}\text{Cu}$ ]Cu-DOTATATE showed preferential accumulation in macrophages, while [ $^{18}\text{F}$ ]FDG was taken up by macrophages and other leukocytes.<sup>19</sup> Although this study was performed in animals, this supports our findings.

Accurate and early detection of inflammatory foci is important for effective treatment of patients with IE, and inconclusive scans can delay the diagnosis, which can potentially be fatal as patients with PVE have high mortality rates.<sup>2,20,21</sup> In our study, a total of six (15%) [ $^{18}\text{F}$ ]FDG PET/CT scans in cases and controls were interpreted as inconclusive, whereas no scans were inconclusive with [ $^{64}\text{Cu}$ ]Cu-DOTATATE. This is a lower rate than that reported in other PET/CT studies. Philip et al<sup>7</sup> found 32 (18%) [ $^{18}\text{F}$ ]FDG PET/CT scans uninterpretable in patients with suspected PVE and excluded these scans in the analysis of sensitivity and specificity. Unlike Philip et al, we included only definite IE cases, and our sample size was smaller, which could explain the lower percentage of inconclusive scans.<sup>7</sup> Similarly, in a study by Tarkin et al of a systematic comparison of [ $^{68}\text{Ga}$ ]Ga DOTATATE for imaging in atherosclerotic inflammation, 27 (64%) of the [ $^{18}\text{F}$ ]FDG PET/CT scans were deemed uninterpretable.<sup>22</sup> In our study, for the purpose of the sensitivity and specificity analysis, the inconclusive scans in the control group counted as a false positive, and the inconclusive scans in the case group counted as a false negative to avoid a false deviation in a positive or negative direction for either of the tracers.

No other studies have evaluated the sensitivity and specificity of [ $^{64}\text{Cu}$ ]Cu-DOTATATE in patients with IE. The sensitivity and specificity in relation to PVE with [ $^{64}\text{Cu}$ ]Cu-

DOTATATE were fairly similar to the sensitivity and specificity found with [ $^{18}\text{F}$ ]FDG PET/CT by Philip et al.<sup>7</sup> However, that study excluded all cases with inconclusive [ $^{18}\text{F}$ ]FDG PET/CT scans, thus the true sensitivity could be lower. In the subanalysis, where we excluded 1 patient, who in retrospect did not have PVE, the sensitivity increased and was higher than that reported by Philip et al.<sup>7</sup> In other larger studies with [ $^{18}\text{F}$ ]FDG PET/CT, the sensitivity for PVE varied (73% to 91%), and the specificity ranged from 80 to 89%.<sup>9,23,24</sup> The sensitivity for NVE with [ $^{64}\text{Cu}$ ]Cu-DOTATATE was low and similar to that found with [ $^{18}\text{F}$ ]FDG PET/CT in previous studies, where the diagnostic value was poor.<sup>25</sup> However, [ $^{64}\text{Cu}$ ]Cu-DOTATATE had a higher specificity for both PVE and NVE, although the difference was not statistically significant, which could be explained by the small sample size.

[ $^{18}\text{F}$ ]FDG PET/CT is the most commonly used nuclear imaging technique for diagnosing a wide range of infectious and inflammatory diseases, including IE.<sup>26</sup> However, it has important limitations regarding specificity and reproducibility as it is based on uptake of a glucose analog and is taken up by metabolically active cells and is not specific for inflammatory cells.<sup>8,9</sup> Furthermore, the prescan preparation, such as fasting and dietary restriction, can be difficult to manage, particularly for in-hospital patients and patients with diabetes.<sup>8,10,11</sup> Compared with [ $^{18}\text{F}$ ]FDG, [ $^{64}\text{Cu}$ ]Cu-DOTATATE has some notable advantages, as it has no significant physiological uptake in normal myocardium and thus does not require any dietary restrictions or fasting before the scan.<sup>27</sup> [ $^{64}\text{Cu}$ ]Cu-DOTATATE could be a promising tracer



**Figure 6.** Overview of the 2x2 tables for both 2-deoxy-2-[ $^{18}\text{F}$ ]-fluoro-d-glucose ( $^{18}\text{F}$ ]FDG; FDG; [white box]) and [ $^{64}\text{Cu}$ ]Cu-DOTATATE (DOTA) positron emission tomography/computed tomography (PET/CT; orange box).

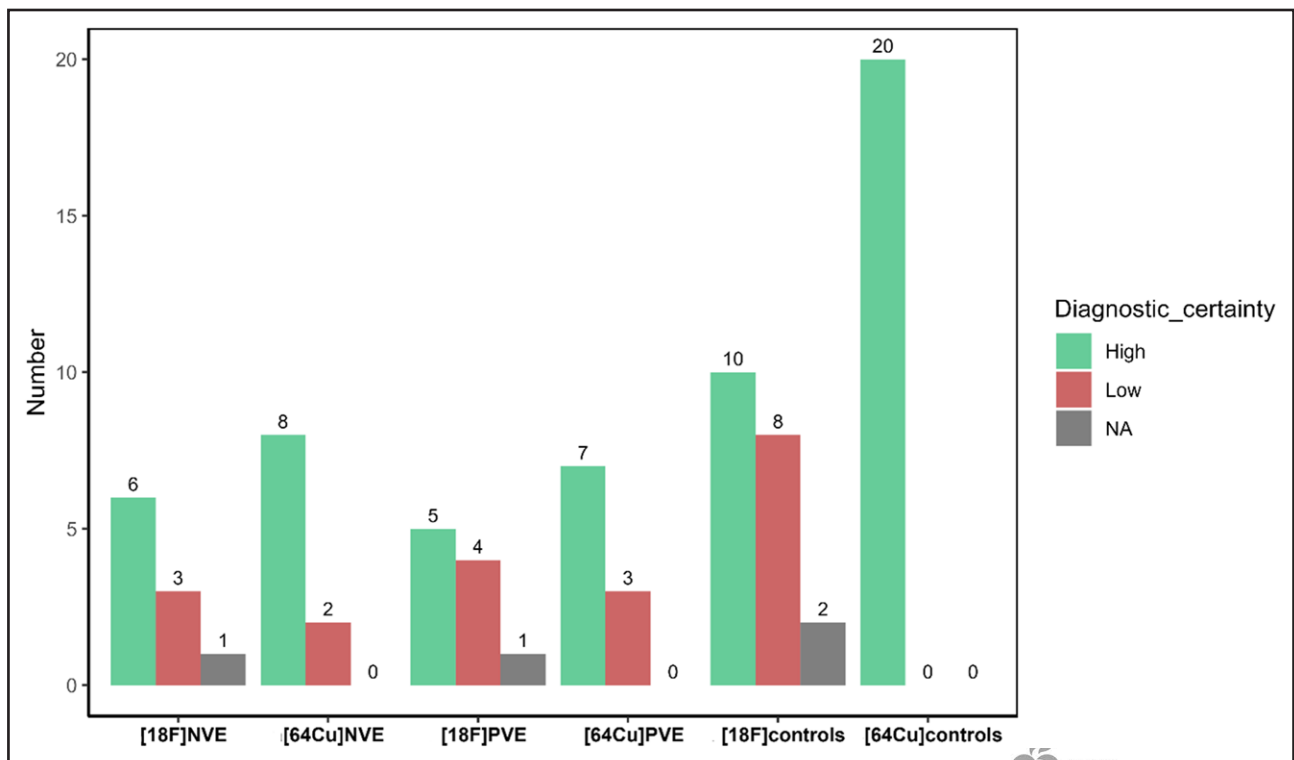
**A**, All cases vs controls. **B**, Native valve endocarditis (NVE) vs controls. **C**, Prosthetic valve endocarditis (PVE) vs controls. IE indicates infective endocarditis.

in patients with PVE. DOTATATE labeled with  $^{68}\text{Ga}$  could be an alternative to [ $^{64}\text{Cu}$ ]Cu-DOTATATE, but due to the shorter positron range of  $^{64}\text{Cu}$  ( $\approx 1$  mm) compared with  $^{68}\text{Ga}$  ( $\approx 4$  mm), translating into less blurred images, we anticipate [ $^{64}\text{Cu}$ ]Cu-DOTATATE in a systematic comparison will have higher accuracy for imaging spatially small changes in the valves similar to previous findings in atherosclerosis and culprit lesions.<sup>22,28</sup> In addition, there are also  $^{18}\text{F}$ -labeled somatostatin analog tracers, which could be tested in the future in patients with IE, when  $^{68}\text{Ga}$  or  $^{64}\text{Cu}$  is not available.<sup>29</sup>

## Strengths and Limitations

The strength of this study is the comprehensive evaluation of IE pathology prospectively using multimodal imaging. The study was hypothesis-generating and exploratory, and it identified [ $^{64}\text{Cu}$ ]Cu-DOTATATE as a potential novel PET/CT tracer for patients with IE, particularly those with PVE. However, our study has some limitations. The study sample was relatively small, and our findings should be validated in a larger sample. The critically ill patients, who could not lay still for  $>20$  minutes, were excluded. In this explorative clinical setting only cases with definite IE were included. Another

limitation of the study was the use of qualitative analysis of cardiac uptake, mainly based on visual interpretation by 1 experienced Chief Physician in nuclear medicine defining sensitivity and specificity; however, the intra-rater variability was low and the intraclass correlation coefficient high. In addition, we cannot rule out the possibility that the quantitative tracer uptake measures could be influenced by intravenous antibiotic treatment (median number of 5 days) before the scan. However, the median number of days between the 2 scans was 2.5; therefore, we expect this would affect both scans equally. This is similar to the clinical setting, where patients during the diagnostic workup already have initiated the antibiotic treatment. Furthermore, bias in the blinding process cannot be excluded, nevertheless the reader analyzing the scans was blinded to the fact, whether the patients had IE or were controls. We think that it is difficult to do it differently in the diagnostic clinical setting. Lastly, the control group of healthy individuals may not be fully representative in comparison to the real-life clinical setting of patients with IE, where various conditions may be present. Thus, in the present study an overestimation of the sensitivity and specificity could be present; however, we expect this would have affected both tracers equally.



**Figure 7. Diagnostic certainty assessment.**

High indicates definitive certainty. Low indicates lower certainty. NA denotes not possible to assess the certainty (related to the inconclusive scans). NVE indicates native valve endocarditis; and PVE, prosthetic valve endocarditis.

## Conclusions

In this novel prospective study comparing  $^{64}\text{Cu}$ ]Cu-DOTATATE and  $^{18}\text{F}$ ]FDG PET/CT in patients with IE,  $^{64}\text{Cu}$ ]Cu-DOTATATE PET/CT showed uptake in infected valves. Both tracers performed equally well in identifying PVE and equally poorly in identifying NVE. Notably, no preparation, dietary restrictions, or fasting is required before  $^{64}\text{Cu}$ ]Cu-DOTATATE PET/CT scan. Finally, in contrast to  $^{18}\text{F}$ ]FDG PET/CT, no  $^{64}\text{Cu}$ ]Cu-DOTATATE PET/CT scans were interpreted as inconclusive. Larger studies are warranted to validate our findings.  $^{64}\text{Cu}$ ]Cu-DOTATATE may prove clinically valuable in PVE and augment diagnostics in this difficult clinical setting.

## ARTICLE INFORMATION

Received May 31, 2024; accepted November 15, 2024.

### Affiliations

Department of Cardiology, Copenhagen University Hospital–Rigshospitalet, Copenhagen (K.H.-T., H.B., L.K., E.L.F.) and Department of Clinical Physiology and Nuclear Medicine, Copenhagen University Hospital–Rigshospitalet, Copenhagen (M.O.F., P.H., J.L., H.H.J., A.K.ær, R.S.R.), Cluster for Molecular Imaging, Copenhagen University Hospital–Rigshospitalet & Department of Biomedical Sciences (M.O.F., A.K.ær, R.S.R.) and Department of Clinical Medicine (H.B., K.I., L.K., R.S.R., E.L.F.), University of Copenhagen, Copenhagen, Denmark Steno Diabetes Center Copenhagen, Copenhagen, Denmark (I.B.R.). Department of Emergency Medicine, Copenhagen University Hospital–Herlev and Gentofte, Herlev, Denmark (K.I.). Department of Cardiology, Zealand University Hospital, Roskilde, Denmark (N.E.B.). Clinical Institutes, Copenhagen and Aalborg Universities, Aalborg, Denmark (N.E.B.). Department of Cardiothoracic Surgery, University Hospital of Copenhagen, Rigshospitalet, Copenhagen, Denmark (C.H.M.). Department of

Cardiology, Bispebjerg and Frederiksberg University Hospital, Copenhagen, Denmark (C.T., R.S.R.).

### Sources of Funding

Supported by the Department of Cardiology and Department of Clinical Physiology and Nuclear Medicine, Copenhagen University Hospital–Rigshospitalet, Copenhagen, Denmark.

### Disclosures

Dr Bull Rasmussen is a full-time employee of Novo Nordisk. Dr Bundgaard receives lecture fees from Amgen, BMS, MSD, Pfizer, and Sanofi. Dr Bruun has received investigator-initiated grants from The Novo Nordisk Foundation, The Augustinus Foundation, The Kaj Hansen Foundation, and Health Insurance Denmark, not related to this study. Dr Tuxen reports speaker fees from Orion Pharma and Novartis and personal fees for advisory board participation from Boehringer Ingelheim and Bayer A/s, all outside the submitted work. Dr Køber has received lecture fees from Astra Zeneca, Bayer, Boehringer, Novartis, and Novo, unrelated to this manuscript. Dr Kjær is an inventor/IPR holder on patent covering  $^{64}\text{Cu}$ -DOTATATE and receives a grant from PERSIMUNE through the Danish National Research Foundation (grant 126). Dr Fosbøl receives Novo Nordisk Foundation and the Danish Heart Association Independent research grants related to valvular heart disease and endocarditis. The other authors report no conflicts.

### Supplemental Material

Figures S1–S6  
Tables S1–S2

## REFERENCES

1. Cahill TJ, Prendergast BD. Infective endocarditis. *Lancet*. 2016;387:882–893. doi: 10.1016/S0140-6736(15)00067-7
2. Wang A, Athan E, Pappas PA, Fowler VGJ, Olaison L, Paré C, Almirante B, Muñoz P, Rizzi M, Naber C, et al; International Collaboration on Endocarditis-Prospective Cohort Study Investigators. Contemporary clinical profile and outcome of prosthetic valve endocarditis. *JAMA*. 2007;297:1354–1361. doi: 10.1001/jama.297.12.1354

3. Toyoda N, Chikwe J, Itagaki S, Gelijns AC, Adams DH, Egorova NN. Trends in infective endocarditis in California and New York State, 1998–2013. *JAMA* 2017;317:1652–1660. doi: 10.1001/jama.2017.4287
4. Bayer AS, Chambers HF. Prosthetic valve endocarditis diagnosis and management—new paradigm shift narratives. *Clin Infect Dis*. 2021;72:1687–1692. doi: 10.1093/cid/ciab036
5. Habib G, Lancellotti P, Antunes MJ, Bongiorni MG, Casalta JP, Del Zotti F, Dulgheru R, El Khoury G, Erba PA, Iung B, et al; ESC Scientific Document Group. 2015 ESC guidelines for the management of infective endocarditis: the Task Force for the Management of Infective Endocarditis of the European Society of Cardiology (ESC). Endorsed by: European Association for Cardio-Thoracic Surgery (EACTS), the European Association of Nuclear Medicine (EANM). *Eur Heart J*. 2015;36:3075–3128. doi: 10.1093/eurheartj/ehv319
6. Li JS, Sexton DJ, Mick N, Nettles R, Fowler VGJ, Ryan T, Bashore T, Corey GR. Proposed modifications to the Duke criteria for the diagnosis of infective endocarditis. *Clin Infect Dis*. 2000;30:633–638. doi: 10.1086/313753
7. Philip M, Tessonier L, Mancini J, Mainardi JL, Fernandez-Gerlinger MP, Lussato D, Attias D, Cammilleri S, Weinmann P, Hagege A, et al. Comparison between ESC and Duke criteria for the diagnosis of prosthetic valve infective endocarditis. *JACC Cardiovasc Imaging*. 2020;13:2605–2615. doi: 10.1016/j.jcmg.2020.04.011
8. Pijl JP, Nienhuis PH, Kwee TC, Glaudemans AWJM, Slart RHJA, Gormsen LC. Limitations and pitfalls of FDG-PET/CT in infection and inflammation. *Semin Nucl Med*. 2021;51:633–645. doi: 10.1053/j.semnuclmed.2021.06.008
9. Gomes A, Glaudemans AWJM, Touw DJ, van Melle JP, Willems TP, Maass AH, Natour E, Prakken NHJ, Borra RJH, van Geel PP, et al. Diagnostic value of imaging in infective endocarditis: a systematic review. *Lancet Infect Dis*. 2017;17:e1–e14. doi: 10.1016/S1473-3099(16)30141-4
10. Boellaard R, Delgado-Bolton R, Oyen WJG, Giammarile F, Tatsch K, Eschner W, Verzijlbergen FJ, Barrington SF, Pike LC, Weber WA, et al; European Association of Nuclear Medicine (EANM). FDG PET/CT: EANM procedure guidelines for tumour imaging: version 2.0. *Eur J Nucl Med Mol Imaging*. 2015;42:328–354. doi: 10.1007/s00259-014-2961-x
11. Balink H, Hut E, Pol T, Flokstra FJ, Roef M. Suppression of <sup>18</sup>F-FDG myocardial uptake using a fat-allowed, carbohydrate-restricted diet. *J Nucl Med Technol*. 2011;39:185–189. doi: 10.2967/jnmt.110.076489
12. Laznick M, Laznickova A, Maecke HR. Receptor affinity and preclinical biodistribution of radiolabeled somatostatin analogs. *Anticancer Res*. 2012;32:761–766.
13. Reubi JC, Schär JC, Waser B, Wenger S, Heppeler A, Schmitt JS, Mäcke HR. Affinity profiles for human somatostatin receptor subtypes SST1–SST5 of somatostatin radiotracers selected for scintigraphic and radiotherapeutic use. *Eur J Nucl Med*. 2000;27:273–282. doi: 10.1007/s002590050034
14. Johnbeck CB, Knigge U, Kjær A. PET tracers for somatostatin receptor imaging of neuroendocrine tumors: current status and review of the literature. *Future Oncol*. 2014;10:2259–2277. doi: 10.2217/fon.14.139
15. Lepidi H, Casalta JP, Fournier PE, Habib G, Collart F, Raoult D. Quantitative histological examination of bioprosthetic heart valves. *Clin Infect Dis*. 2006;42:590–596. doi: 10.1086/500135
16. Harris PA, Taylor R, Thielke R, Payne J, Gonzalez N, Conde JG. Research electronic data capture (REDCap)—a metadata-driven methodology and workflow process for providing translational research informatics support. *J Biomed Inform*. 2009;42:377–381. doi: 10.1016/j.jbi.2008.08.010
17. Zauner F, Glück T, Salzberger B, Ehrenstein B, Beutel G, Robl F, Hanses F, Birnbaum D, Linde HJ, Audebert F. Are histopathological findings of diagnostic value in native valve endocarditis? *Infection*. 2013;41:637–643. doi: 10.1007/s15010-013-0404-4
18. Morris AJ, Drinkovic D, Pottumarthy S, Strickett MG, MacCulloch D, Lambie N, Kerr AR. Gram stain, culture, and histopathological examination findings for heart valves removed because of infective endocarditis. *Clin Infect Dis*. 2003;36:697–704. doi: 10.1086/367842
19. Toner YC, Ghotbi AA, Naidu S, Sakurai K, van Leent MMT, Jordan S, Ordikhani F, Amadori L, Sofias AM, Fisher EL, et al. Systematically evaluating DOTATATE and FDG as PET immuno-imaging tracers of cardiovascular inflammation. *Sci Rep*. 2022;12:6185. doi: 10.1038/s41598-022-09590-2
20. Lalani T, Chu VH, Park LP, Cecchi E, Corey GR, Durante-Mangoni E, Fowler VGJ, Gordon D, Grossi P, Hannan M, et al; International Collaboration on Endocarditis—Prospective Cohort Study Investigators. In-hospital and 1-year mortality in patients undergoing early surgery for prosthetic valve endocarditis. *JAMA Intern Med*. 2013;173:1495–1504. doi: 10.1001/jamainternmed.2013.8203
21. Vongpatanasin W, Hillis LD, Lange RA. Prosthetic heart valves. *N Engl J Med*. 1996;335:407–416. doi: 10.1056/NEJM199608083350607
22. Tarkin JM, Joshi FR, Evans NR, Chowdhury MM, Figg NL, Shah AV, Starks LT, Martin-Garrido A, Manavaki R, Yu E, et al. Detection of atherosclerotic inflammation by (68)Ga-DOTATATE PET compared to [<sup>18</sup>F]FDG PET imaging. *J Am Coll Cardiol*. 2017;69:1774–1791. doi: 10.1016/j.jacc.2017.01.060
23. Pizzi MN, Roque A, Fernández-Hidalgo N, Cuéllar-Calabria H, Ferreira-González I, González-Alujas MT, Oristrell G, Gracia-Sánchez L, González JJ, Rodríguez-Palomares J, et al. Improving the diagnosis of infective endocarditis in prosthetic valves and intracardiac devices with <sup>18</sup>F-fluorodeoxyglucose positron emission tomography/computed tomography angiography: initial results at an infective endocarditis referral center. *Circulation*. 2015;132:1113–1126. doi: 10.1161/CIRCULATIONAHA.115.015316
24. Saby L, Laas O, Habib G, Cammilleri S, Mancini J, Tessonier L, Casalta JP, Gouret F, Ribéri A, Avierinos JF, et al. Positron emission tomography/computed tomography for diagnosis of prosthetic valve endocarditis: increased valvular <sup>18</sup>F-fluorodeoxyglucose uptake as a novel major criterion. *J Am Coll Cardiol*. 2013;61:2374–2382. doi: 10.1016/j.jacc.2013.01.092
25. Philip M, Delcourt S, Mancini J, Tessonier L, Cammilleri S, Arregle F, Martel H, Oliver L, Hubert S, Renard S, et al. <sup>18</sup>F-fluorodeoxyglucose positron emission tomography/computed tomography for the diagnosis of native valve infective endocarditis: a prospective study. *Arch Cardiovasc Dis*. 2021;114:211–220. doi: 10.1016/j.jacvd.2020.10.005
26. Hess S, Blomberg BA, Zhu HJ, Høiland-Carlson PF, Alavi A. The pivotal role of FDG-PET/CT in modern medicine. *Acad Radiol*. 2014;21:232–249. doi: 10.1016/j.jacr.2013.11.002
27. Pfeifer A, Knigge U, Mortensen J, Oturai P, Berthelsen AK, Loft A, Binderup T, Rasmussen P, Elema D, Klausen TL, et al. Clinical PET of neuroendocrine tumors using <sup>64</sup>Cu-DOTATATE: first-in-humans study. *J Nucl Med*. 2012;53:1207–1215. doi: 10.2967/jnumed.111.101469
28. Malmberg C, Ripa RS, Johnbeck CB, Knigge U, Langer SW, Mortensen J, Oturai P, Loft A, Hag AM, Kjær A. <sup>64</sup>Cu-DOTATATE for noninvasive assessment of atherosclerosis in large arteries and its correlation with risk factors: head-to-head comparison with 68Ga-DOTATOC in 60 patients. *J Nucl Med*. 2015;56:1895–1900. doi: 10.2967/jnumed.115.161216
29. Leupe H, Ahenkorah S, Dekervel J, Untertiner M, Van Cutsem E, Verslype C, Cleeren F, Deroose CM. <sup>18</sup>F-labeled somatostatin analogs as PET tracers for the somatostatin receptor: ready for clinical use. *J Nucl Med Off Publ Soc Nucl Med*. 2023;64:835–841. doi: 10.2967/jnumed.123.265622